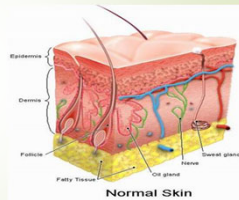


Evaluation and Treatment of Skin Injuries

Carol O'Mara DNP, APRN, FNP-C
Robert Hieger, MSN, APRN, FNP
September 2019

Composition of skin

- Skin consists of four layers
 - Epidermis
 - Dermis
 - Superficial fascia (SQ layer)
 - Deep fascia



Wounds

- **Assessment:**
 - History of present condition
 - Type of injury
 - Blunt vs. penetrating
 - Extent of contamination
 - Location of injury
 - Time since injury
 - Mechanism of injury
 - Care and treatment after injury
 - Prior to arrival
 - Occurred at work or home
 - Past medical history
 - If hand injury
 - Which hand is dominant
 - Immunizations – tetanus
 - Allergies
 - Medications
 - Alcohol / other drug ingestion

Wound Assessment and Documentation

- Length of wound
- Anatomic location
- Depth of wound
- Foreign body
- Function of area and region distal
- Neuromuscular and vascular assessment of the area around and distal to the wound
 - Do prior to anesthesia
- Jewelry

Wounds – Physical exam

- Is bleeding controlled?
- Depth, length, width, & nature of wound
- Extent of bruised or necrotic tissue
- Flaps of skin too thin for adequate vascularity
- Obvious skin / wound contamination
- Function preserved or lost in affected part
- Underlying fracture
- Possible foreign body
- The 6 P's of evaluation
 - Pain
 - Pallor
 - Pulses
 - Paresthesia
 - Paralysis
 - Pressure

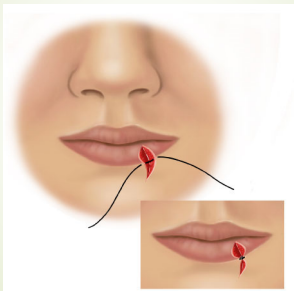
Closure pearls

- Close all structural layers
- Treat the tissues gently
 - Do not add trauma
- Approximate the dermal – dermal interface
 - This layer is the only wound edge to heal by primary intention
- If area of tension or possible inversion
 - Vertical mattress suture

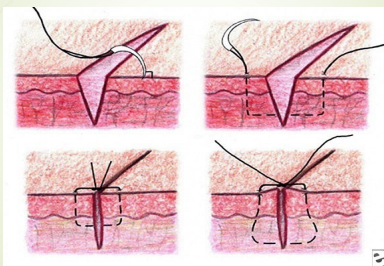
Closure pearls

- Beware of puncture wounds
- Beware of bites
 - Particularly human
 - Cosmesis a concern
- Close the vermillion border of the lip first
 - Use chromic inside of the wet-dry line

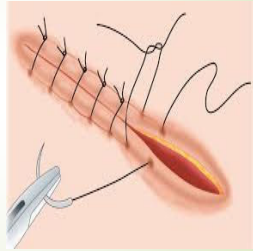
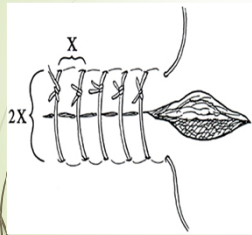
Closing the vermillion border



Needle placement



Simple interrupted

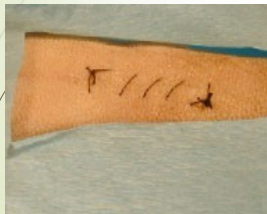

Video on Simple Interrupted

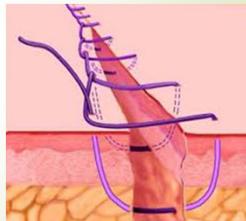
■ <https://www.youtube.com/watch?v=VmaenFTww9w>

Running stitch

Running stitch



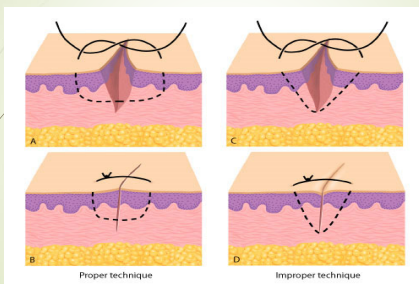
Running locked stitch



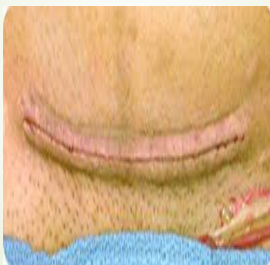
Video on Running Stitch

■ <https://www.youtube.com/watch?v=xnm5s5iN1V4>

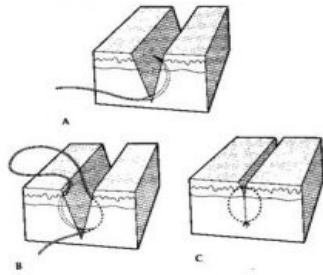
Wound eversion



Wound eversion



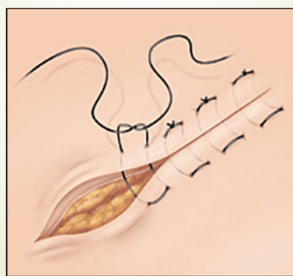
Subcutaneous (buried) suture



Buried Subcuticular simple

■ <https://www.youtube.com/watch?v=Vq7upcvzgUc> -

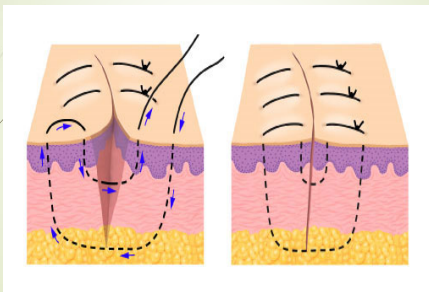
Horizontal Mattress Suture



Horizontal Mattress Suture

- https://www.youtube.com/watch?v=z4_L9I6H1EA

Vertical Mattress



Vertical Mattress Suture

- <https://www.youtube.com/watch?v=9qdB7NKQWRo>

Anesthesia- injectable

- Act by diffusing across neural sheaths and interfere with depolarization
 - Given subdermal
 - Blocks c-fibers only; still have vibration
- Esters (Novacaine, Cocaine)
 - Rarely used unless "amides" contraindicated
- Amides (lidocaine, sensorcaine/bupivacaine)
 - Most common usage

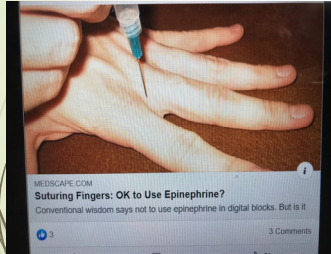Pharmacology of Local Anesthetics

- Local anesthetics have a lipid soluble hydrophobic aromatic group and a hydrophilic amide group
- Ester linkage more easily broken than amide
- Amide is heat stable
- Esters produce para-aminobenzoate (PABA) which causes allergic reactions.
- Work by interfering with sodium influx across the nerve membrane
- High lipid solubility allows for neural sheath solubility
- Drug passes through lipid membrane if unionized
- Alkaline environment required for drug to be unionized

Injectable Anesthesia

- | | |
|---|--|
| <ul style="list-style-type: none">■ Lidocaine■ Tolerated to a dose of 4 mg/kg■ For 70 kg patient what is a potentially lethal subdermal injection?■ Small gauge needle■ Combine with NaHCO₃ at 1:10 ratio■ Can be combined with epinephrine<ul style="list-style-type: none">■ Avoid blood flow sensitive areas■ The "age old rule" of "no epinephrine" in fingers, nose, penis, toes may be crumbling! | <ul style="list-style-type: none">■ Toxicity■ Cardiovascular<ul style="list-style-type: none">■ Myocardial inhibitory effects cause hypotension and bradycardia■ Excitatory central nervous system<ul style="list-style-type: none">■ Can induce seizures■ Vasovagal syncope<ul style="list-style-type: none">■ Most common reaction■ Condition transient■ Patient should lie down during suturing |
|---|--|
- Paine, D. 2019, Sept. 17 "Data on use of epinephrine in digits"

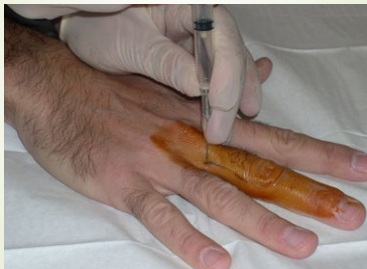Studies on “Use of Epinephrine in Extremities”



Article

■ http://ms.spr.ly/6188TPcBs?fbclid=IwAR2lQ5du5c27uX649CqFLak7LpJ5AMthxyog4qkauX_igo68bmw4qPrP7LY

Digital block



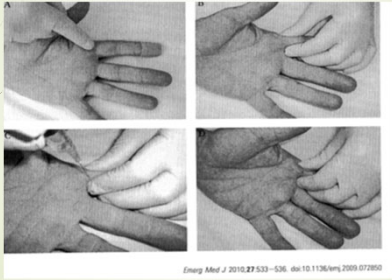
Single injection digital blocks

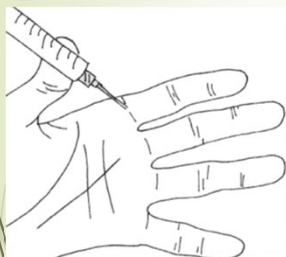

Figure 3. One Injection Digital Anesthesia

Figure 1 Single injection subcutaneous digital nerve block technique. (A) Landmark. Identify the proximal skin crease on the volar aspect of the injured finger. (B) After cleaning the skin, use one hand to gently pinch the soft tissues of the finger just distal to the skin crease. (C) Insert the needle (25G) just beneath the skin at the midpoint of the skin crease. Inject 2–3 millilitres of warmed 0.5% bupivacaine into the soft tissues. (D) Massage the anaesthetic into the soft tissues.

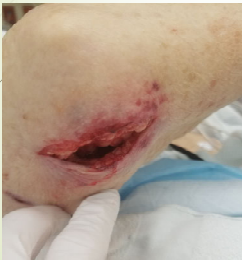One injection digital block



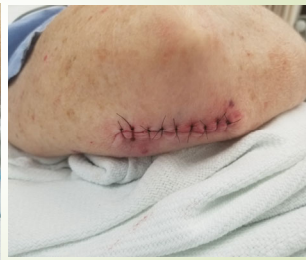Volar Digital Block – one point

■ <https://www.youtube.com/watch?v=G6jyw7l3bZs> –

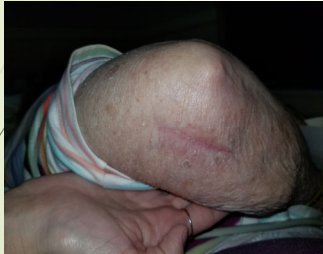Before



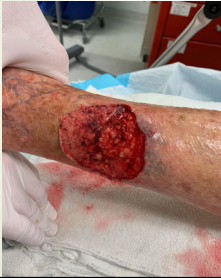After



1 month later



Before



After





